

Mast Cells in Cutaneous Allergic Vasculitis: A Case Report

Hiroaki Inamura¹, Yasushi Igarashi¹, Yayoi Kashiwase¹, Junichiro Morioka¹, Katsuhiro Suzuki¹ and Motohiro Kurosawa¹

ABSTRACT

Background: The mechanism of cutaneous allergic vasculitis still remains unclear, and to the best of our knowledge, no case has been reported in the literature in which the number of mast cells was examined.

Methods: A 33-year-old woman, with a past history of allergic rhinitis due to Japanese cedar and *Phleum pratense* (timothy), presented with a chief complaint of palpable papules on both lower legs in December 2002. On blood examination, peripheral blood eosinophilia was present, but all other examinations for immunologic diseases were negative, including specific IgE. We suspected cutaneous allergic vasculitis and performed skin biopsy.

Results: In December 2002, histological examination of biopsy specimens of the skin lesions showed leukocytoclastic vasculitis. The diagnosis of cutaneous allergic vasculitis was made based on the clinical symptoms and the pathological findings of biopsy specimens. Immunohistochemical staining for human mast cell tryptase using monoclonal antibody against human mast cell tryptase showed an accumulation of mast cells. Treatment with oral corticosteroid resulted in the disappearance of clinical symptoms, and the steroid tapered. A second skin biopsy was performed in June 2005 after informed consent was obtained. Histological examination showed no findings of leukocytoclastic vasculitis, and the number of mast cells had decreased. She has been well without treatment.

Conclusions: Mast cells may increase in the skin lesion of cutaneous allergic vasculitis.

KEY WORDS

allergic cutaneous vasculitis, case report, immunohistochemical staining, leukocytoclastic vasculitis, mast cell

INTRODUCTION

Cutaneous allergic vasculitis is a pathologically necrotizing vasculitis localized in the skin and characterized by the involvement of cutaneous small blood vessels.¹ Clinically, the skin lesions are polymorphic and palpable papules on the lower legs are generally recognized. The histological features are vascular and perivascular infiltration of neutrophils with leukocytoclasia, endothelial cell swelling, fibrin deposition and erythrocyte extravasation.²⁻⁷ Although infections, drugs, and associated diseases are suspected to be the etiological agents,⁸ its mechanism still remains unclear. To the best of our knowledge, there has been no case report of cutaneous allergic vasculitis in the literature in which the number of mast cells was investigated. Here we report a case of the disease in which an accumulation of mast cells in the skin lesion

was demonstrated.

CLINICAL SUMMARY

A 33-year-old woman, who had a past history of allergic rhinitis due to Japanese cedar and *Phleum pratense* (timothy), presented at our hospital in December 2002 because of a symmetric appearance of solid papules with itching on both lower legs. The size of the papules ranged from a few millimeters up to ten millimeters. She had no symptoms of allergic rhinitis and was not taking any medication at that point. The peripheral blood leukocyte was 6600 / μ l (basophils 0.3%, eosinophils 10.3%, neutrophils 60.6%, lymphocytes 23.4%, monocytes 5.4%). The serum levels were as follows: IgG = 1251 mg/dl, IgA = 196 mg/dl, IgM = 115 mg/dl, IgE = 130 IU/ml. Serum complement levels were also normal (CH₅₀ = 37.9 U/ml; C3 = 79 mg/dl; C4 = 20 mg/dl; C1q = 2.4 μ g/ml). Antinu-

¹Gunma Institute for Allergy and Asthma, Gunma, Japan.
Correspondence: Dr. Motohiro Kurosawa, Gunma Institute for Allergy and Asthma, 3233-1 Shinozuka, Ohra-machi, Gunma 370-0615, Japan.

Email: motohiro@shin-ourahp.or.jp
Received 29 August 2005. Accepted for publication 26 January 2006.

©2006 Japanese Society of Allergology

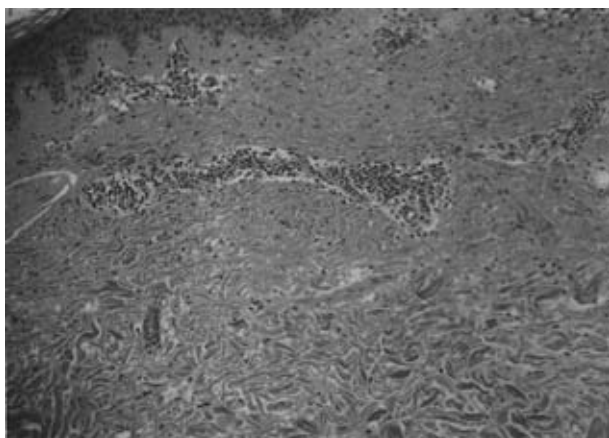


Fig. 1 Hematoxylin-eosin staining of the biopsy specimen from the skin lesion, showing an infiltration of neutrophils and decreased number of eosinophils in the blood vessel circumference (magnification $\times 100$).

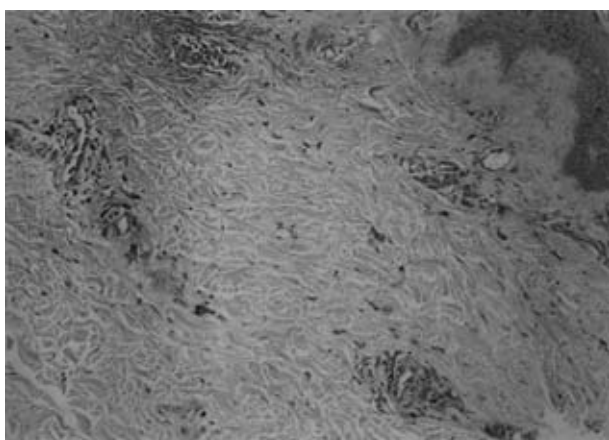


Fig. 2 Toluidine blue staining of the biopsy specimen from the skin lesion, showing the presence of metachromatic cells (magnification $\times 100$).

clear antibody was negative. The urinalysis and renal values were normal. On the next day, the peripheral blood leukocyte count increased to 9100 / μ l and the number of eosinophils also increased (basophils 1.1%, eosinophils 14.4%, neutrophils 69.6%, lymphocytes 10.5%, monocytes 4.4%). The CRP level was 0.09 mg/dl. LE factor, RA test, and anti-DNA antibody were all negative. Biopsy from the skin lesions of the thigh was performed in December 2002. A diagnosis of cutaneous allergic vasculitis was made based on the clinical symptoms and pathological findings of biopsy specimens described below. The skin lesions improved after treatment with oral corticosteroid and the number of eosinophils decreased (WBC 5900 / μ l, eosinophil 6.2%) in January 2003. The steroid was

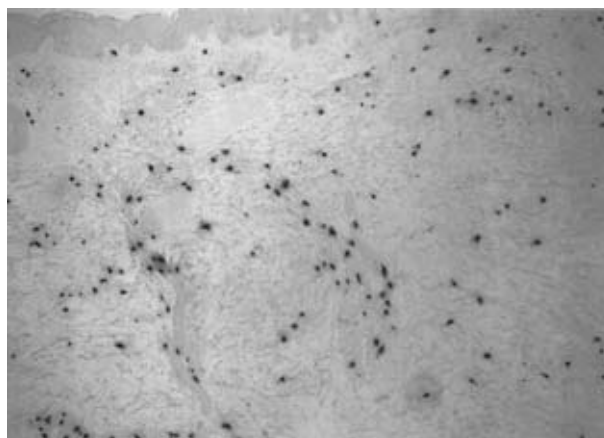


Fig. 3 Immunohistochemical staining for human mast cell tryptase of the biopsy specimen from the skin lesion, showing the presence of mast cells (magnification $\times 100$).

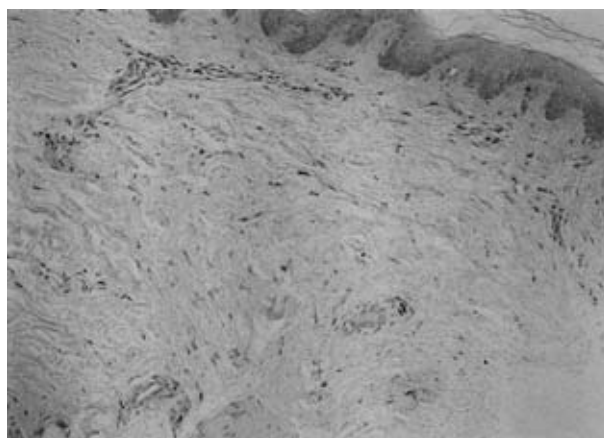


Fig. 4 Toluidine blue staining of the biopsy specimen after the skin condition improved (magnification $\times 100$).

then tapered and discontinued 3 weeks after its commencement. The patient was well without any therapy until June 2005, when a second skin biopsy was performed after informed consent was obtained. The patient has not suffered from any palpable papules since.

PATHOLOGICAL FINDINGS

Hematoxylin-eosin staining of the biopsy specimens, which was performed in December 2002, showed an increased number of neutrophils and decreased number of eosinophils in the blood vessel circumference (Fig. 1). These findings were compatible with the diagnosis of cutaneous allergic vasculitis. Toluidine blue staining showed the presence of metachromatic cells in the interstitium (Fig. 2).

Immunohistochemical staining of the biopsy specimens for human mast cell tryptase using monoclonal




Fig. 5 Immunohistochemical staining for human mast cell tryptase of the biopsy specimen after the skin condition improved (magnification $\times 100$).

antibody against human mast cell tryptase (Chemicon, Temecula, CA, USA) showed the presence of mast cells (Fig. 3). On the other hand, the number of mast cells in the biopsy specimens obtained in June 2005 was markedly decreased both on toluidine blue staining (Fig. 4) and on immunohistochemical staining (Fig. 5). The mast cells were counted using an Olympus BX-50 microscope equipped with a 0.1×0.1 mm ocular grid (Olympus Eyepiece Micrometer U-OCMSQ 10/10, Tokyo, Japan) in 8 grid fields, and the mean of the number of mast cells was analyzed. The number of mast cells in the skin biopsy specimens taken in December 2002 and June 2005 was $82.8/\text{mm}^2$ and $20.2/\text{mm}^2$, respectively. The number of metachromatic cells was comparable with that in the corresponding biopsy specimens on immunohistochemical staining.

DISCUSSION

Cutaneous leukocytoclastic vasculitis was formerly called allergic cutaneous vasculitis or hypersensitivity vasculitis. The report of the Chapel Hill Consensus Conference in 1994⁹ defined cutaneous allergic vasculitis as leukocytoclastic vasculitis localized in the skin without systemic vasculitis or glomerulonephritis, and stated that this type of vasculitis is dominant for adult women especially in the lower legs and dorsum pedis areas.

Although the mechanism of this disease still remains obscure, possible involvement of allergic reaction has been suspected. Soter *et al.*¹⁰ showed the findings of mast cell degranulation in cutaneous necrotizing venulitis. Tosca and Stratigos¹¹ advocated that mast cells might play a central role in allergic cutaneous vasculitis. Grunwald *et al.*¹² suggested possible involvement of mast cells in hypersensitive angitis

by the degranulation test of mast cells. However, to the best of our knowledge, there has been no case report of allergic cutaneous vasculitis in which the number of mast cells was investigated.

In this report, we examined the number of mast cells in the skin of allergic cutaneous vasculitis. The mean number of mast cells in the skin lesions and the skin after healing was $82.8/\text{mm}^2$ and $20.2/\text{mm}^2$, respectively, indicating an increase in the number of mast cells in the skin lesion in our present case. However, the second biopsy was performed 2.5 years after the first biopsy. It is therefore uncertain whether the biopsy specimens represented the effect of improvement or not. Further studies are required. In conclusion, this is the first report of cutaneous allergic vasculitis showing an accumulation of mast cells in the skin lesion.

REFERENCES

1. Lever WF, Schaumburg-Lever G. Vascular disease. In: Lever WF, Schaumburg-Lever G (eds). *Histopathology of the Skin*, 7th edn. Philadelphia: JB Lippincott, 1990;188-191.
2. Braverman IM, Yen A. Demonstration of immune complexes in spontaneous and histamine-induced lesions and in normal skin of patients with leukocytoclastic angitis. *J. Invest. Dermatol.* 1975;**64**:105-112.
3. Gower RG, Sams WM Jr, Thorne EG, Kohler PF, Claman HN. Leukocytoclastic vasculitis: sequential appearance of immunoreactants and cellular changes in serial biopsies. *J. Invest. Dermatol.* 1977;**69**:477-484.
4. Sams WM Jr, Claman HN, Kohler PF, McIntosh RM, Small P, Mass MF. Human necrotizing vasculitis: immunoglobulins and complement in vessel walls of cutaneous lesions and normal skin. *J. Invest. Dermatol.* 1975;**64**:441-445.
5. Soter NA, Mihm MC Jr, Gigli I, Dvorak HF, Austen KF. Two distinct cellular patterns in cutaneous necrotizing angitis. *J. Invest. Dermatol.* 1976;**66**:344-350.
6. Sams WM Jr, Thorne EG, Small P, Mass MF, McIntosh RM, Stanford RE. Leukocytoclastic vasculitis. *Arch. Dermatol.* 1976;**112**:219-226.
7. Smoller BR, McNutt NS, Contreras F. The natural history of vasculitis. What the histology tells us about pathogenesis. *Arch. Dermatol.* 1990;**126**:84-89.
8. Sams WM Jr. Necrotizing vasculitis. *J. Am. Acad. Dermatol.* 1980;**3**:1-13.
9. Jennette JC, Falk RJ, Andrassy K *et al.* Nomenclature of systemic vasculitides. Proposal of an international consensus conference. *Arthritis Rheum.* 1994;**37**:187-192.
10. Soter NA, Mihm MC Jr, Dvorak HF, Austen KF. Cutaneous necrotizing venulitis: a sequential analysis of the morphological alterations occurring after mast cell degranulation in a patient with a unique syndrome. *Clin. Exp. Immunol.* 1978;**32**:46-58.
11. Tosca N, Stratigos JD. Possible pathogenetic mechanisms in allergic cutaneous vasculitis. *Int. J. Dermatol.* 1988;**27**:291-296.
12. Grunwald MH, Halevy S, Livni E. Allergic vasculitis induced by hydrochlorothiazide: confirmation by mast cell degranulation test. *Isr. J. Med. Sci.* 1989;**25**:572-574.