

Drug-induced Hypersensitivity Syndrome Associated with a Marked Increase in Anti-paramyxovirus Antibody Titers in a Scleroderma Patient

Taio Naniwa¹, Shinji Maeda¹, Hiroo Sawada², Yuko Watanabe¹, Tomoyo Osawa¹, Yoshihito Hayami¹, Shogo Banno¹, Akimichi Morita³ and Ryuzo Ueda¹

ABSTRACT

Background: Drug-induced hypersensitivity syndrome (DIHS) is characterized by a severe multiorgan hypersensitivity reaction that usually appears after prolonged exposure to certain drugs and may be related to reactivation of herpes viruses. There have been few reports regarding the clinical association of DIHS with pathogens other than herpes viruses.

Case Summary: We report a case of scleroderma with DIHS associated with paramyxovirus infection. A 61-year-old man with early diffuse cutaneous scleroderma with myositis and progressive interstitial pneumonia developed generalized erythema with high fever 3 weeks after taking sulfamethoxazole/trimethoprim. The diagnosis of DIHS was made based on the patient's history of using an offending drug, clinical manifestations and laboratory data showing peripheral eosinophilia with the presence of atypical lymphocytes. Virological tests showed significant increases of antibody titers against mumps virus and parainfluenza virus type 2, which strongly suggested that paramyxovirus infection occurred during the clinical course of DIHS.

Discussion: These findings suggest that paramyxovirus infection had contributed to the development of DIHS in this patient and that there is a need to seek evidence of other viral infections in some cases of DIHS, especially those without herpes virus reactivation/infection.

KEY WORDS

cyclophosphamide, drug hypersensitivity, mumps virus, parainfluenza virus, sulfamethoxazole/trimethoprim

INTRODUCTION

Drug-induced hypersensitivity syndrome (DIHS) or drug rash with eosinophilia and systemic symptoms (DRESS) syndrome is characterized by a severe, potentially fatal, multiorgan hypersensitivity reaction, and has been reported to be associated with only a limited number of drugs, such as anticonvulsants, dapsone, allopurinol, sulfasalazine, and sulfamethoxazole/trimethoprim.¹⁻⁵ A maculopapular rash that often progresses to exfoliative erythroderma, fever,

lymphadenopathy, eosinophilia, atypical lymphocytosis, liver dysfunction are the major clinical signs of this syndrome that typically develops two to six weeks after starting an offending drug. The pathogenesis of this disease is not well defined, however, several clinical studies have revealed possible etiologic roles of reactivation of members of the human herpesvirus family, including human herpesvirus 6 (HHV-6), cytomegalovirus (CMV), and Epstein-Barr virus (EBV).^{2,3,6-8}

Paramyxoviridae, which includes the human

¹Division of Rheumatology, Department of Internal Medicine and Molecular Science, ³Department of Geriatric and Environmental Dermatology, Nagoya City University Graduate School of Medical Sciences, Aichi and ²Department of Dermatology, Inabe General Hospital, Mie, Japan.

Correspondence: Dr. Taio Naniwa, Division of Rheumatology, Department of Internal Medicine and Molecular Science, Nagoya City

University Graduate School of Medical Sciences, Kawasumi, Mizuho-ku, Nagoya-city, Aichi 467-8601, Japan.

Email: tnanawa@med.nagoya-cu.ac.jp

Received 8 September 2006. Accepted for publication 8 December 2006.

©2007 Japanese Society of Allergology

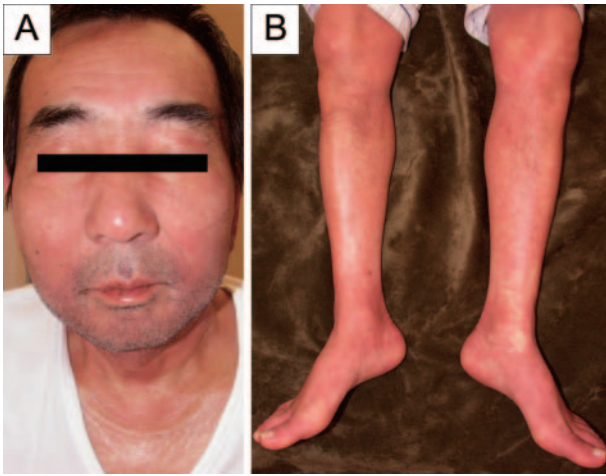


Fig. 1 Diffuse erythema superimposed on the shiny and taut skin in the face and neck (A). Widespread erythematous macules and papules coalesced into diffuse erythema in the lower limbs (B).

parainfluenza viruses, mumps virus, measles virus, and human respiratory syncytial virus, is a single-strand RNA virus.⁹ Human parainfluenza virus type 2, type 4, and mumps virus are classified in the genus *Rubulavirus*, subfamily *Paramyxovirinae*, and share common antigens with each other.⁹⁻¹¹

There has been no report suggesting a possible association between DIHS and paramyxovirus infection. In the present report, we describe a case of a patient with early diffuse cutaneous scleroderma who developed DIHS associated with a significant increase in anti-mumps virus and anti-parainfluenza virus type 2 antibody titers, which strongly suggests active paramyxovirus infection may have had some role in the pathogenesis of DIHS in this patient.

CLINICAL SUMMARY

A 61-year-old man was admitted to this hospital in November 2004 because of fever, skin erythema, and worsening of dyspnea. He had a past history of mumps at the age of five, and pulmonary tuberculosis at the age of thirty. The history of drug allergies was unremarkable except for urticaria after taking a non-steroidal anti-inflammatory drug. He had been in stable condition with mild exertional dyspnea due to pulmonary emphysema, until June 2004, when he noticed swelling in his lower legs and worsening of exertional dyspnea. Thereafter edematous skin thickening emerged and progressed rapidly from the extremities and face to the proximal portion of the body, and he visited our hospital in July 2004. The presence of diffuse skin thickening and a skin biopsy revealed that he had diffuse cutaneous SSc. Myalgia, elevated muscle enzymes, myogenic changes on the single fiber electromyography, and high-resolution computed tomography revealed that he also had

myositis and interstitial pneumonia. Rapid progression of skin sclerosis with muscle and lung involvement suggested very high disease activity with a poor prognosis. Low dose corticosteroid and intravenous cyclophosphamide were started from August 2004 to suppress the progression of interstitial pneumonia, myositis, and diffuse edematous skin lesion. Six weeks before admission, low dose sulfamethoxazole/trimethoprim was started for chemoprevention of *Pneumocystis jiroveci* pneumonia. Three weeks before admission, transient high fever with common cold-like symptoms lasting for two days occurred and subsequently skin rash in the trunk emerged. Intravenous cyclophosphamide infusion was discontinued. Subsequently, the skin rash temporarily disappeared. One week before admission, fever and generalized erythematous skin rash re-emerged and shortness of breath worsened, after which he was admitted to this hospital.

On admission, his temperature was 37.1°C, pulse 90 beats per minute and regular, and blood pressure 80/63 mm Hg. The skin showed erythroderma including facial erythema and findings consistent with diffuse cutaneous scleroderma (Figs. 1A, B), but no evidence of lymphadenopathy or hepatosplenomegaly. Altered consciousness and headache were absent. Chest exam revealed bilateral basilar fine crackles. Major salivary gland or testicular swelling were not present. Laboratory data on admission were as follows: WBC 20,900/ μ l (eosinophil 48%, atypical lymphocyte 3%), hemoglobin 14.3 g/dl, platelet 203×10^3 / μ l, blood urea nitrogen 20 mg/dl, creatinine 1.0 mg/dl, LDH 640 U/l, normal transaminases, CK 339 IU/l, Aldolase 26.4 IU/l, CRP 0.72 mg/dl, IgG 2380 mg/dl, IgA 443 mg/dl, IgM 175 mg/dl, IgE 975 IU/l, antinuclear antibodies $\times 160$ with speckled pattern, and anti-Scl-70, anti-RNP was negative. A specimen of arterial blood, drawn while the patient was breathing ambient air, showed hypoxia with hypocapnia (pCO₂ 28.2 Torr, pO₂ 60.1 Torr). The urinalysis was unremarkable. The chest radiograph and computed tomography showed progression of interstitial pneumonia.

Hypersensitivity reaction due to sulfamethoxazole/trimethoprim use was strongly suspected. Withdrawal of sulfamethoxazole/trimethoprim resulted in a slight improvement in his skin rash and apparently decreased the peripheral blood eosinophil and atypical lymphocyte counts. For the treatment of progressive interstitial pneumonia, administration of intravenous cyclophosphamide at 400 mg was re-started on the eighth hospital day. On the tenth hospital day, he developed a high fever with worsening of generalized erythematous maculopapular rash that progressed to exfoliating erythroderma. Peripheral blood eosinophil and atypical lymphocyte counts increased again. High dose corticosteroid therapy starting with intravenous administration of methylprednisolone 0.25 g

DIHS with Paramyxovirus Infection

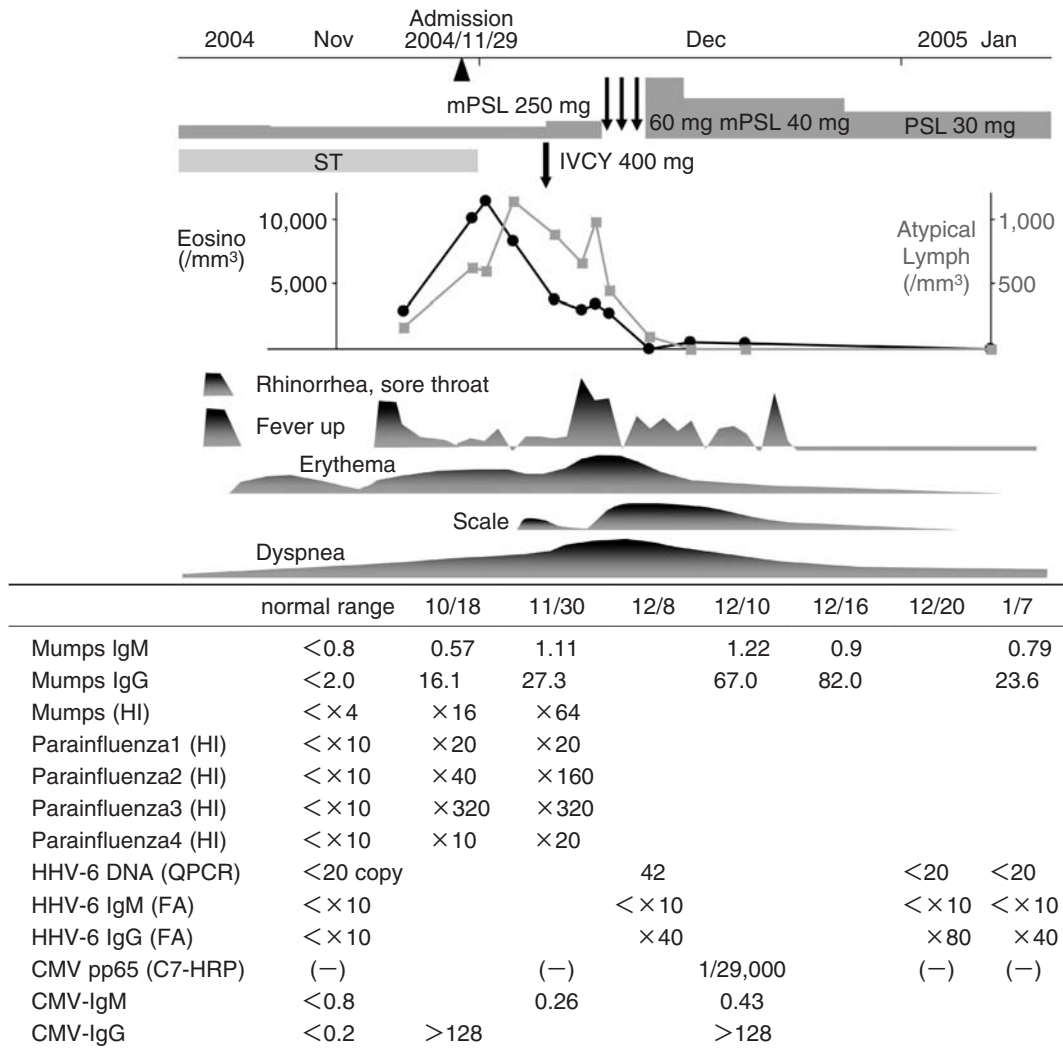


Fig. 2 Clinical course. Abbreviations: CMV, cytomegalovirus; FA, fluorescence antibody test; HHV-6, human herpes virus 6; HI, hemagglutinin inhibition test; HRP, horse radish peroxidase; IVCY, intravenous cyclophosphamide; mPSL, methylprednisolone; PSL, prednisolone; QPCR, quantitative polymerase chain reaction assay; ST, sulfamethoxazole/trimethoprim; VCA, viral capsid antigen. Viral antibody titers without description of assay were measured by enzyme-linked immunosorbent assay. CMV pp65 (C7-HRP) is the quantitative assay for CMV pp65 antigen positive leukocyte count in the peripheral blood determined using horse radish peroxidase conjugated monoclonal antibody C7.

for three days, followed by 60 mg for three days, and 40 mg for 12 days immediately resolved his fever and improved his skin rash and dyspnea. Thereafter the dose of corticosteroid was gradually tapered without relapse of fever, erythematous skin lesions, hematological abnormalities, or hypoxia. A chest CT obtained 14 weeks after admission showed marked improvement of his interstitial pneumonia. Edematous skin changes were slightly improved, however, the modified Rodnan total skin thickness score was not obviously changed (24 on admission, 23 at 3 months after admission).

Virological tests showed significant increases in

IgG and IgM antibody titers against the mumps virus. Although there was a slight increase in HHV-6 DNA measured by quantitative polymerase chain reaction assay and CMV pp65 antigen positive leukocyte in peripheral blood measured by immunostaining using monoclonal antibody C7, significant serological responses to HHV-6 and CMV were not demonstrated. Furthermore, there were no significant increases in antibody titers against human herpes simplex virus, EBV, measles, or rubella. Due to a possible serological cross reactivity between the mumps virus and parainfluenza virus, we retrospectively analyzed anti-parainfluenza virus (type1-4) antibody titers by a he-

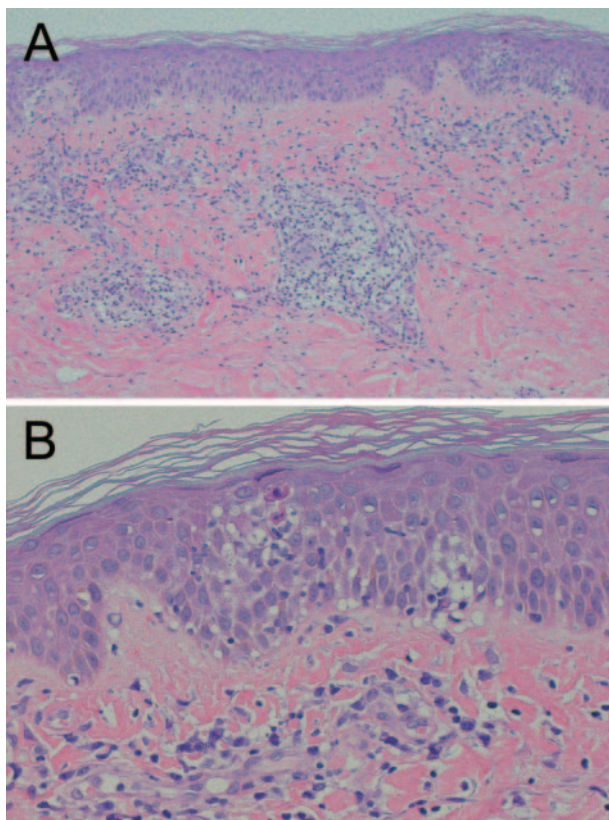


Fig. 3 Microscopic examination of findings from a skin lesion on the middle portion of the left lower leg shows infiltration of mononuclear cells in the epidermis and perivascular infiltration of lymphocytic cells in the dermis (**A**, hematoxylin-eosin, original magnification of $\times 20$). Magnified image of epidermis shows infiltration of lymphocytic cells in the epidermis with necrotic keratinocytes and partial liquefaction degeneration of basal cells (**B**, hematoxylin-eosin, original magnification of $\times 200$).

magglutinin inhibition test and found a 4-fold increase of anti-parainfluenza virus type 2 antibodies between the preserved sera obtained before the onset of DIHS and those on admission (Fig. 2).

PATHOLOGICAL FINDINGS

A skin biopsy specimen obtained from the erythematous lesion of the patient's left lower leg on admission showed lymphocytic infiltration in the epidermis with necrotic keratinocytes, partial liquefaction degeneration of basal cells, and perivascular lymphocytic infiltration in the dermis (Figs. 3A, B). These findings were compatible with the diagnosis of a drug eruption.

DISCUSSION

The clinical findings of this patient consisting of a high fever with maculopapular rashes progressing to exfoliative erythroderma, marked eosinophilia, and

atypical lymphocytosis, three weeks after starting sulfamethoxazole/trimethoprim, lead us to consider the diagnosis of DIHS elicited by sulfamethoxazole/trimethoprim. Rapid worsening of interstitial lung disease after the onset of DIHS was thought to be due to emergence of lung involvement of DIHS superimposed on scleroderma-related interstitial lung disease. Liver dysfunction, which can often be seen in patients with DIHS, was not observed in this patient.

Although the etiology of DIHS has remained largely unknown, human herpes viruses, especially HHV-6, have been explored as a potential etiological candidates in the pathogenesis of DIHS due to the clinical similarities between DIHS and infection or reactivation of the herpes virus family.^{2,3,12,13} Several reports also showed possible etiological associations of DIHS with cytomegalovirus, Epstein-Barr virus, human herpes virus-7 and human immunodeficiency virus,^{2,3,6-8,12-16} though there have been few reports regarding possible etiological association of DIHS with other pathogens.^{17,18}

The novel finding of this case was that the significant increase in anti-mumps virus IgG and IgM titers were demonstrated in the course of DIHS. Mumps virus has been a well-known pathogen of epidemic parotitis, meningitis/encephalitis, hearing loss, orchitis/oophoritis, and myocarditis. Mumps virus infections usually induce lifelong immunity and reinfection of this virus is rare.¹⁰ Several *in vitro* studies showed that the mumps virus could persistently infect human synovial tissue cells or some human cell lines,^{19,20} however, latent mumps virus infection, as well as parainfluenza virus, has not been clinically confirmed.¹⁰

Although reactivation of mumps virus in the course of DIHS had never been confirmed by the demonstration of serological response to the mumps virus or the elevated levels of viral genome or antigens in the patients' specimens, Shiohara T *et al.* reported that bilateral swelling of the salivary glands with severe xerostomia, suggesting mumps virus infection, was frequently observed as an initial presentation of DIHS.²¹ Such signs were not observed in our patient.

On the other hand, reinfection of human parainfluenza viruses, major pathogens of acute respiratory infections, is common. Mumps virus and human parainfluenza virus type 2 belong to the subfamily *Paramyxovirinae*, genus *Rubulavirus* and share minor common envelope antigens and have serological cross-reactivity.²² Parainfluenza virus infections can cause a rise of mumps antibody titers and contribute to the lifelong stability of the anti-mumps antibody.¹⁰ Based on these view points, the increase in antibodies to mumps virus and parainfluenza virus type 2 seen in this patient might be due to parainfluenza virus type 2 infection. Although there has been no reports showing possible etiological associations of DIHS with paramyxovirus infection, the relationship

between the clinical symptoms and anti-viral immune response in this patient suggest a possible etiological role of paramyxovirus infection in the pathogenesis of DIHS in this patient.

Another distinctive point of this case was the deterioration after administration of cyclophosphamide during the course of DIHS. We used cyclophosphamide prior to high-dose corticosteroids to suppress excessive immune reactions and to treat skin and lung involvement, because the use of high-dose corticosteroid in early diffuse scleroderma has been reported as a risk factor or trigger of renal crisis^{23,24} and cyclophosphamide has not been reported as an offending drug in DIHS. Consequently, worsening of skin and lung involvement with an increase of atypical lymphocyte and eosinophil counts in the peripheral blood was observed after administration of intravenous cyclophosphamide.

However, patients with DIHS may have a fluctuating course and the flare up of DIHS after administration of cyclophosphamide in this patient might not be related to cyclophosphamide. Two possible modes of action of cyclophosphamide that may induce deterioration of DIHS are suggested from previous experimental and clinical findings. First, administration of cyclophosphamide has been shown to enhance viral replications, which in turn induces deterioration of DIHS.^{25,26} The pretreatment with cyclophosphamide enhanced the multiplication of influenza virus in mouse models.²⁵ In a patient with systemic lupus erythematosus and human immunodeficiency virus infection, serum levels of HIV-RNA increased after intravenous cyclophosphamide, and decreased after cessation of cyclophosphamide.²⁶ Second, cyclophosphamide induces immune deviation favoring eosinophilic inflammation, which is a distinct hematological finding of DIHS, in certain animal models and human diseases.²⁷⁻²⁹ In ovalbumin sensitized BALB/c mice, cyclophosphamide worsened features of allergic pulmonary inflammation in association with increased production of IgE and Th2 cytokines by suppressing regulatory T cells.²⁷ In patients with multiple sclerosis, treatment with methylprednisolone plus cyclophosphamide increased not only anti-CD3-induced but antigen-driven IL-4 secretion by T cells, which was associated with eosinophilia.^{28,29}

In conclusion, we report a scleroderma patient who developed DIHS after administration of sulfamethoxazole/trimethoprim and cyclophosphamide and demonstrate serological evidence of active paramyxovirus infection during the course of DIHS. Administration of cyclophosphamide worsened DIHS and high-dose corticosteroid improved it. This case report suggests that there is a need to seek evidence of other viral infections in cases of DIHS without herpes virus reactivation/infection, and that immunosuppression with cyclophosphamide should not be used in the course of DIHS. Further clinical and experimental studies

are needed to clarify the pathogenesis of DIHS and etiological associations of paramyxovirus or other viral infections and DIHS.

REFERENCES

1. Roujeau JC, Stern RS. Severe adverse cutaneous reactions to drugs. *N. Engl. J. Med.* 1994;**331**:1272-1285.
2. Suzuki Y, Inagi R, Aono T *et al.* Human herpesvirus 6 infection as a risk factor for the development of severe drug-induced hypersensitivity syndrome. *Arch. Dermatol.* 1998;**134**:1108-1112.
3. Tohyama M, Yahata Y, Yasukawa M *et al.* Severe hypersensitivity syndrome due to sulfasalazine associated with reactivation of human herpesvirus 6. *Arch. Dermatol.* 1998;**134**:1113-1117.
4. Hicks ME, Smith CL, Stein GE. Trimethoprim/sulfamethoxazole-induced hypersensitivity syndrome. *Ann. Pharmacother.* 1997;**31**:1259.
5. Mainra RR, Card SE. Trimethoprim-sulfamethoxazole-associated hepatotoxicity—part of a hypersensitivity syndrome. *Can. J. Clin. Pharmacol.* 2003;**10**:175-178.
6. Morimoto T, Sato T, Matsuoka A *et al.* Trimethoprim-sulfamethoxazole-induced hypersensitivity syndrome associated with reactivation of human herpesvirus-6. *Intern. Med.* 2006;**45**:101-105.
7. Descamps V, Mahe E, Houhou N *et al.* Drug-induced hypersensitivity syndrome associated with Epstein-Barr virus infection. *Br. J. Dermatol.* 2003;**148**:1032-1034.
8. Aihara M, Sugita Y, Takahashi S *et al.* Anticonvulsant hypersensitivity syndrome associated with reactivation of cytomegalovirus. *Br. J. Dermatol.* 2001;**144**:1231-1234.
9. Lamb RA, Kolakofsky D. *Paramyxoviridae: The Viruses and Their Replication.* In: Knipe DM, Howley PM (eds). *Fields Virology.* 4th edn. Vol. 1. Philadelphia: Lippincott Williams & Wilkins, 2001;1305-1340.
10. Carbone KM, Wolinsky JS. *Mumps Virus.* In: Knipe DM, Howley PM, (eds). *Fields Virology.* 4th edn. Vol. 1. Philadelphia: Lippincott Williams & Wilkins, 2001; 1381-1400.
11. Tanabayashi K, Takeuchi K, Hishiyama M *et al.* Nucleotide sequence of the leader and nucleocapsid protein gene of mumps virus and epitope mapping with the in vitro expressed nucleocapsid protein. *Virology* 1990;**177**: 124-130.
12. Descamps V, Valance A, Edlinger C *et al.* Association of human herpesvirus 6 infection with drug reaction with eosinophilia and systemic symptoms. *Arch. Dermatol.* 2001;**137**:301-304.
13. Sullivan JR, Shear NH. The drug hypersensitivity syndrome: what is the pathogenesis? *Arch. Dermatol.* 2001;**137**:357-364.
14. Mitani N, Aihara M, Yamakawa Y *et al.* Drug-induced hypersensitivity syndrome due to cyanamide associated with multiple reactivation of human herpesviruses. *J. Med. Virol.* 2005;**75**:430-434.
15. Hashizume H, Takigawa M. Drug-induced hypersensitivity syndrome associated with cytomegalovirus reactivation: immunological characterization of pathogenic T cells. *Acta Derm. Venereol.* 2005;**85**:47-50.
16. Rotunda A, Hirsch RJ, Scheinfeld N *et al.* Severe cutaneous reactions associated with the use of human immunodeficiency virus medications. *Acta Derm. Venereol.* 2003;**83**:1-9.
17. Regnier S, Descamps V, Boui M *et al.* Parvovirus B19 infection mimicking drug-induced hypersensitivity syndrome. *Ann. Dermatol. Venereol.* 2000;**127**:505-506.

18. Kosseian-Bal I, Bocquet H, Beneton N *et al.* Hypersensitivity syndrome during *Mycoplasma pneumoniae* infection. *Ann. Dermatol. Venereol.* 1998;**125**:328-330.
19. Huppertz HI, Chantler JK. Restricted mumps virus infection of cells derived from normal human joint tissue. *J. Gen. Virol.* 1991;**72** (Pt 2):339-347.
20. Hariya Y, Shirakawa S, Yonekura N *et al.* Augmentation of verotoxin-induced cytotoxicity/apoptosis by interferon is repressed in cells persistently infected with mumps virus. *J. Interferon. Cytokine Res.* 1999;**19**:479-485.
21. Shiohara T, Inaoka M, Kano Y. Drug-induced Hypersensitivity Syndrome (DIHS): A Reaction Induced by a Complex Interplay among Herpesviruses and Antiviral and Antidrug Immune Responses. *Allergol. Int.* 2006;**55**:1-8.
22. Chanock RM, Murphy BR, Collins PL. *Parainfluenza Viruses*. In: Knipe DM, Howley PM, (eds). *Fields Virology*. 4th edn. Vol. 1. Philadelphia: Lippincott Williams & Wilkins, 2001;1341-1379.
23. Steen VD, Medsger TA Jr. Case-control study of corticosteroids and other drugs that either precipitate or protect from the development of scleroderma renal crisis. *Arthritis Rheum.* 1998;**41**:1613-1619.
24. Naniwa T, Banno S, Takahashi N *et al.* Normotensive scleroderma renal crisis with diffuse alveolar damage after corticosteroid therapy. *Mod. Rheumatol.* 2005;**15**:134-138.
25. Abou-Donia H, Jennings R, Potter CW. The spread and persistence of influenza viruses in normal and cyclophosphamide-treated mice. *J. Med. Virol.* 1981;**7**:251-262.
26. Alonso CM, Lozada CJ. Effects of IV cyclophosphamide on HIV viral replication in a patient with systemic lupus erythematosus. *Clin. Exp. Rheumatol.* 2000;**18**:510-512.
27. Su YC, Rolph MS, Cooley MA *et al.* Cyclophosphamide augments inflammation by reducing immunosuppression in a mouse model of allergic airway disease. *J. Allergy Clin. Immunol.* 2006;**117**:635-641.
28. Smith DR, Balashov KE, Hafler DA *et al.* Immune deviation following pulse cyclophosphamide/methylprednisolone treatment of multiple sclerosis: increased interleukin-4 production and associated eosinophilia. *Ann. Neurol.* 1997;**42**:313-318.
29. Karni A, Balashov K, Hancock WW *et al.* Cyclophosphamide modulates CD4+ T cells into a T helper type 2 phenotype and reverses increased IFN-gamma production of CD8+ T cells in secondary progressive multiple sclerosis. *J. Neuroimmunol.* 2004;**146**:189-198.